



THE AUSTRALASIAN COLLEGE
OF DERMATOLOGISTS

Seborrhoeic Keratoses

Also known as ... Age Warts, Senile Warts, Brown Warts

What are Seborrhoeic Keratoses?

Seborrhoeic keratoses are benign "wart-like" growths on the skin. Seborrhoeic keratoses affect all racial groups and most commonly appear after the age of 40 years although some people may develop them earlier.

They are often considered unsightly in appearance.

What causes Seborrhoeic Keratoses?

Seborrhoeic keratoses are benign (non-cancerous) growths of the skin.

The exact cause of seborrhoeic keratoses is unknown although they do tend to occur more frequently with increasing age. Their appearance is thought to be part of the normal ageing process of the skin.

What do Seborrhoeic Keratoses look like?

Seborrhoeic keratoses are "wart-like" growths. They are usually raised above the surface of the skin and appear to be stuck on like "barnacles".

Seborrhoeic keratoses occur in varying shades of brown from light to very dark brown. The surface of seborrhoeic keratoses usually feels rough and warty. They can sometimes be dry and scaly and become itchy or irritated.

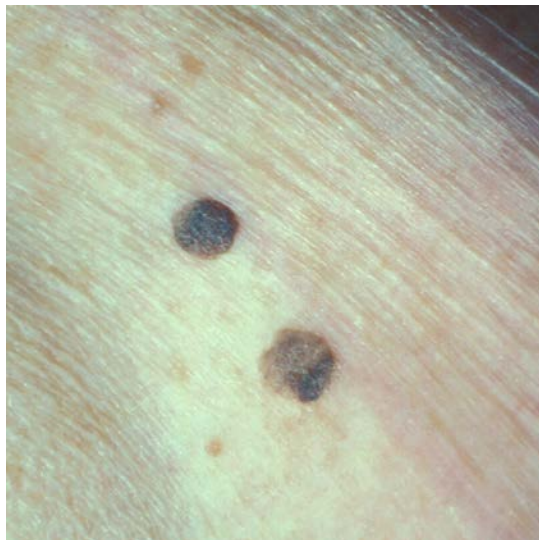


Image reproduced with permission Department of Dermatology St Vincent's Hospital Melbourne

Most people will have more than one seborrhoeic keratosis and some people may have hundreds scattered over the body. They can appear anywhere on the body including the

scalp, face and genitals. In a condition called dermatosis papulosis nigra hundreds of small seborrhoeic keratoses are present on the face and neck.

Sometimes seborrhoeic keratoses are flat and pale and can resemble freckles. Sometimes they can be large (up to many centimetres in size) and may resemble skin tumours.

They often appear quite suddenly.

What other problems may occur with Seborrhoeic Keratoses?

In rare cases the sudden development of widespread, multiple (hundreds) seborrhoeic keratoses may be associated with an underlying malignant tumour.

How are Seborrhoeic Keratoses diagnosed?

The diagnosis of a seborrhoeic keratosis is usually made by clinical examination.

Very dark lesions which have changed in some way or which are growing rapidly may need a biopsy to confirm the diagnosis and exclude the possibility of skin cancer.

Darker lesions that look irregular should be checked by a doctor to ensure that they are not melanoma.

How are Seborrhoeic Keratoses treated?

Seborrhoeic keratoses do not need any specific treatment.

Usually seborrhoeic keratoses are treated for cosmetic reasons or because they have become itchy or irritated. People affected with seborrhoeic keratoses often complain that they "catch" on things, bleed or become inflamed, especially if they are large and warty.

Seborrhoeic keratoses are usually treated by freezing them with liquid nitrogen (cryotherapy). They can also be removed surgically by lightly scraping (shave excision or curettage) or burning the lesions (electrocautery). Laser resurfacing (ablative laser) and strong medical-grade chemical peels may also be used.

All methods of removal have an increased risk of permanent colour change (lightening or darkening) or scarring of the skin. Removing seborrhoeic keratoses will not prevent new lesions from developing in the future.

There is no known effective prevention of these lesions.

What is the prognosis or likely outcome of Seborrhoeic Keratoses?

Seborrhoeic keratoses do not cause any major health problems. Some people affected by this condition may be troubled by the cosmetic appearance of the lesions. Lesions can be traumatised accidentally by scratching and may bleed or become itchy or inflamed.

This information has been written by Dr Nicholas Aspres